

# Photorejuvenation

## Non-Ablative Skin Rejuvenation Using Intense Pulsed Light

Mark S. Nestor, M.D., Ph.D.  
David J. Goldberg, M.D.  
Mitchel P. Goldman, M.D.  
Robert A. Weiss, M.D.  
Darrell S. Rigel, M.D.

*As our population matures, we have become aware of both the intrinsic and extrinsic factors that cause our skin to appear older.*

*Great numbers of our patients are looking for rejuvenation procedures to eradicate or minimize the inevitable ravages of time.*

*Today's active lifestyles mean that patients are requesting procedures with little or no "downtime."*

# PHOTOREJUVENATION

Non-Ablative Skin Rejuvenation Using Intense Pulsed Light *continued from cover*

The overall appearance of aging skin is primarily related to the quantitative effects of sun exposure with resultant UV damage of structural components such as collagen and elastic fibers. Appearance, however, is also affected by genetic factors, intrinsic factors, disease processes such as rosacea, and the overall loss of cutaneous elasticity associated with age. Many patients have exposed themselves to vast amounts of sun during activities of everyday life and recreation. Along with thinning of the ozone and other factors, this has made visible signs of aging, damage and disease evident in younger and younger individuals. We are seeing patients in their twenties and thirties presenting with solar elastosis, telangiectasias, lentigines and rhytid formation. In the older population and those individuals with extensive sun exposure, these changes are magnified.

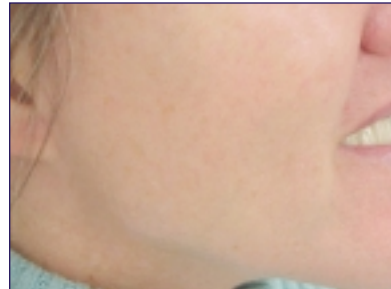
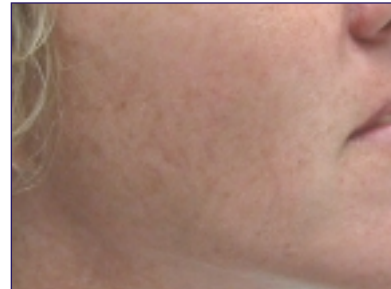
Figure 1. Type I Photorejuvenation. Photoaging and dyschromia, before (left), and after 3 IPL treatments using the 570nm filter, 40 J/cm<sup>2</sup> (right). Robert A. Weiss, MD, Hunt Valley, MD.

In the past decade, a dramatic transformation of rejuvenation procedures has occurred. It began with dermabrasion and deep chemical peels progressing to deeper laser resurfacing. Although effectively dealing with some aspects of cutaneous photoaging, these were usually associated with significant downtime and side effects. While patients have benefited dramatically from ablative CO<sub>2</sub> and erbium resurfacing, as well as lasers for vascular and pigmented lesions, many of them cannot tolerate these procedures—

either because of associated pain, potential side effects, or prolonged downtime with loss of income.

Presently, there is pent-up demand for the new generation of non-ablative treatments that promises dramatic improvement for the visible signs of aging, photo damage and intrinsic disease with low risk and, perhaps most importantly, no “downtime”.

## New Definitions

A number of different classification systems for photo damage have been proposed. Most widely used is the Glogau classification system<sup>1</sup>, which itemizes various aspects of photo damage and photoaging, including precancerous conditions and frank skin cancers.

Another delineation of rhytides ranges from dynamic to static as proposed by Fitzpatrick et al<sup>2</sup>. There is currently no consistent model, however, to precisely define the types of photoaging that are amenable to newly available techniques of non-ablative Photorejuvenation. To eliminate confusion associated with differing descriptions, we propose a new, simple system that classifies and defines Photorejuvenation by the most common extrinsic and intrinsic cutaneous aging and photo damage changes, in order to specifically aid in the patient selection process and to guide discussion of present and future techniques.

	Indications
<b>Type I Photorejuvenation</b>	<ul style="list-style-type: none"> <li>• Benign vascular lesions, including:               <ul style="list-style-type: none"> <li>– telangiectasias</li> <li>– symptoms of rosacea</li> <li>– flushing</li> </ul> </li> <li>• Dyschromia</li> <li>• Erythema following laser resurfacing</li> <li>• Pigmentary sun damage</li> <li>• Mottled Pigmentation</li> <li>• Hyperpigmentation</li> <li>• Photoaging</li> <li>• Lentigines</li> </ul>
<b>Type II Photorejuvenation</b>	<ul style="list-style-type: none"> <li>• Dermal and epidermal structural changes</li> <li>• Rhytides</li> <li>• Elastotic changes</li> <li>• Collagenous and connective tissue changes</li> <li>• Large pores</li> </ul>

Figure 2. Summary of Photorejuvenation indications

**Group A Skin Damage** includes mottled pigmentation, lentigines, as well as vascular changes including telangiectasias and erythema that can be seen both as a result of early to moderate photo damage or intrinsic processes such as rosacea.

**Group B Skin Damage** includes dermal and epidermal structural changes, such as rhytides, large pores, as well as significant elastotic change manifested as a cobblestone, ruddy appearance.

Individual patients may develop elements of either or both Group A and Group B. Patients with advanced cutaneous aging and/or photoaging may often manifest both types of change. This classification system is structured to easily delineate signs and symptoms of intrinsic and extrinsic aging amenable to non-ablative intervention in the vast majority of the population, and suggest to the physician the most effective technique for treatment.

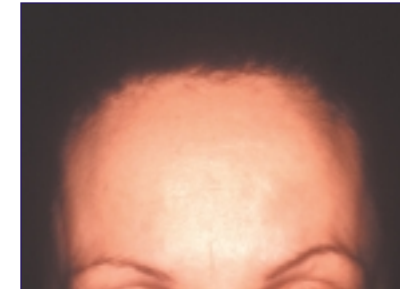
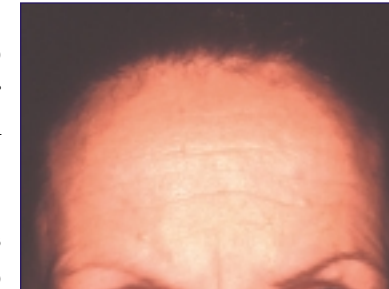


Figure 3. Type II Photorejuvenation. Wrinkles on forehead (left). Improvement seen 6 months after 4 IPL treatments (right). David J. Goldberg, MD, Westwood, NJ.

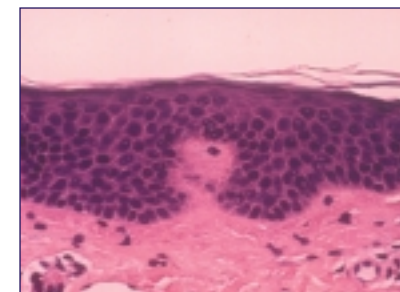
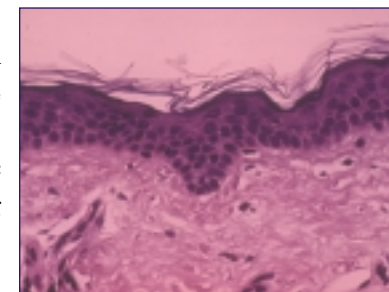


Figure 4. Type II Photorejuvenation histology. Solar elastosis in upper dermis, before treatment (left). Dermal thickening and new collagen formation, 6 months after 4 IPL treatments (right). David J. Goldberg, MD, Westwood, NJ.

## Photorejuvenation Techniques

**Photorejuvenation** is a dynamic non-ablative process defined as the use of non-coherent, intense pulsed light (IPL™) in a low fluence non-ablative manner to rejuvenate the skin. The treatment is generally administered in a series of four to six procedures in 3-week intervals. In most cases, the entire face is treated, rather than a limited affected area for a uniform and aesthetically pleasing result. The patient may return to all activities immediately after the procedure. Epidermal cooling or topical anesthetic may be used electively.

On the basis of appropriate indications for treatment (the previously described Skin Damage Groups A and B) the Photo Rejuvenation techniques are further defined as **Type I** and **Type II**.

**Type I Photorejuvenation** is used for treatment of Group A skin damage, such as changes involving the pigmentary effects of sun damage, hyperpigmentation, mottled pigmentation, lentigines, and lesions and dyschromia of benign vascular origin, including telangiectasias, symptoms of rosacea, flushing, as well as erythema following laser resurfacing and other procedures.

**Type II Photorejuvenation** is used for Group B skin damage, involving changes of collagenous and connective tissue origin, including pore size, elastosis and rhytides. Type II Photorejuvenation techniques may involve combined technologies, such as IPL treatments alternated with Nd:YAG laser treatments.

The Photorejuvenation process can significantly improve skin damage of both Groups A and B in a single program of treatment, defining a standard for non-ablative therapy using intense pulsed light. These definitions are inclusive of types of intense pulsed light treatments for skin rejuvenation known by other nomenclature, such as FotoFacial™, PhotoFacial™, EpiFacial™, FacialLight™, and many others.

## Intense Pulsed Light (IPL) and the Photorejuvenation Process

While many forms of coherent laser light are currently being studied and used for their effects on

# PHOTOREJUVENATION

## Non-Ablative Skin Rejuvenation Using Intense Pulsed Light

*continued*

specific aspects of photo damage, including resurfacing and rejuvenation, IPL technology, as utilized in the ESC Sharplan PhotoDerm®, MultiLight™, EpiLight™, and new platforms under development, offers unique characteristics ideal for the photorejuvenation process. IPL is filtered and multi-spectral; its emitted wavelengths, ranging from approximately 550 to 1200nm, are limited by a filter which selectively blocks and defines the lowest wavelength. While the shorter wavelengths are effective in removing unwanted vascular and pigmented lesions, the longer wavelength energy is available to rejuvenate the skin.

Additionally, IPL is extremely flexible in pulse duration; the pulse width can be varied extensively. Systems also have the ability to join pulses in double and even triple strings of “micropulses”. It is because of its combined multichromatic wavelength and pulse duration versatility that IPL has the unique ability to simultaneously treat the pigmentary and vascular changes associated with Group A and B skin changes in what we define as **Type I Photorejuvenation**.

Low fluence IPL treatments given in intervals of approximately 3 weeks have been clinically shown to dramatically decrease the appearance of telangiectasias and other vascular lesions, as well as lentiginos and other pigmentary changes (see Figure 1). Histology studies (Figure 4) correlate with these clinical changes and show dramatic reversal in photo damage and age-related changes. Thus, patients treated by a number of sessions of non-ablative IPL Photorejuvenation, can benefit from the process, with both the vascular and pigmentary changes taking place simultaneously. These patients include both those with early to moderate photo damage and those who primarily manifest telangiectasias and rosacea. Additionally, early data suggests that IPL technology alternated with treatments with

the ESC Sharplan Vasculight™ 1064 nm Nd:YAG laser, or other combined technology programs, may also be used to accomplish Type II Photorejuvenation. In this protocol, both clinical and histological improvement is seen in solar elastosis, rhytides, enlarged pores and elastotic dermal changes.

Clinical protocols suggest optimal outcomes require an average of four to six treatment sessions spaced approximately three weeks apart. Patients may be pretreated with topical anesthetic and may experience darkening of lentiginos and hyperpigmented areas for a short period of time. As the treatments progress, significant clinical improvement can be seen.

## CONCLUSIONS

**Type I and Type II Photorejuvenation** using intense pulsed light holds the tremendous promise of allowing us to treat a large percentage of patients who present with Group A or Group B skin changes, a variety of conditions ranging from vascular and/or pigmentary abnormalities to the collagenous and connective tissue changes characterized by rhytides. Patients can see dramatic benefit after a series of treatments, which can be characterized as not painful, truly non-ablative, and offering the very valuable lifestyle factor of “no downtime”. The resulting procedure has been recognized for minimal adverse effects, excellent long term results, and a very high measure of patient satisfaction.

## References

<sup>1</sup>Glogau R: Physiologic and structural changes associated with aging skin. *Dermatol Clin* 1997 Oct;15(4):555-9.

<sup>2</sup>Fitzpatrick RE, Goldman MP, Satur MP, Tope WD: Pulsed carbon dioxide laser resurfacing of photoaged skin. *Arch Dermatol* 132:395, 1996.



### ESC Sharplan Headquarters - The Americas

ESC Medical Systems, Inc.  
100 Morse Street  
Norwood, MA 02062 USA  
Tel 781.278.7600  
Tel 800.562.5916  
Fax 781.278.7700

PhotoDerm is a registered trademark, and MultiLight, EpiLight, Vasculight and IPL are trademarks of ESC Medical Systems, Inc.

Intense Pulsed Light is cleared for permanent hair reduction in skin types I - V, photoepilation in types I - VI, treatment for benign vascular lesions and malformations, portwine stains, hemangiomas, untreated facial, truncal or leg telangiectasia and/or reticular veins in types I - IV, and treatment of benign pigmented lesions and tattoos in types I - V.